

Complications of Pulmonary Hydatid Cysts Disease

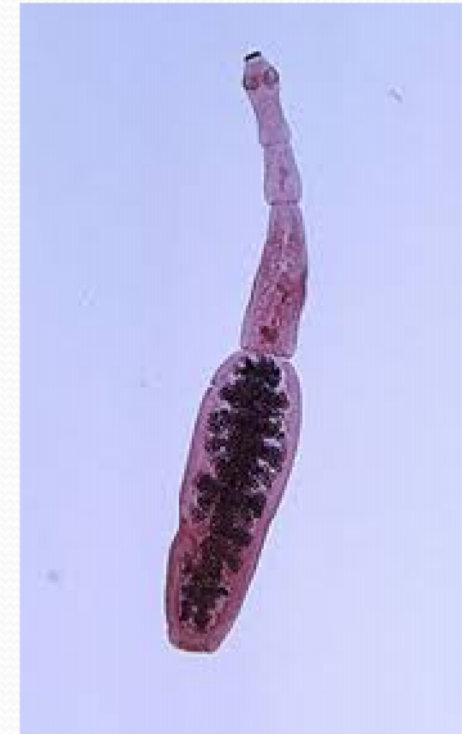*Prof. Bassam Darwish
Almouasat University Hospital
Damascus*

*Scientific meeting of the syrian thoracic association
Damascus ,14 Nov.2019*

Complications of Pulmonary Hydatid Cysts Disease

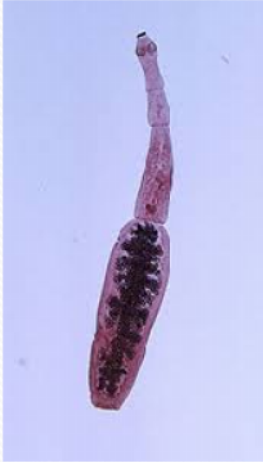Introduction

- *Echinococcus is one of the common infections around the world*
- *Remains a serious health problem in developing countries. **Syria is one of them.***



العبء الصحي و الاقتصادي العالمي من داء الأكياس المائية

- 1 مليون مصاب سنوياً بالعالم
- 1 مليون- 3 ملايين سنة من سنوات العمر المصححة باحتساب مدة العجز¹ كل سنة DALY
- ثلاثة مليارات دولار : التكاليف السنوية
- لعلاج البشر
- وخسائر في قطاع الثروة الحيوانية.

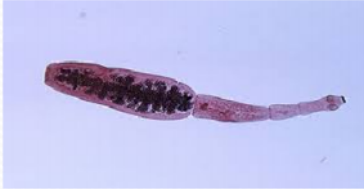

بحث علمي في جامعة حماه

● الكيسة العدارية و الكيسة المذنبة دقيقة الرقبة في
الأغنام و الماعز في سوريا

عبد الكريم خالد

مجلة جامعة دمشق للعلوم الزراعية (2001) المجلد 18- العدد الثاني –
الصفحات 28-36



ملخص الكيسة العذارية في الأغنام و الماعز في سوريا 2001

دراسة د عبد الكريم خالد



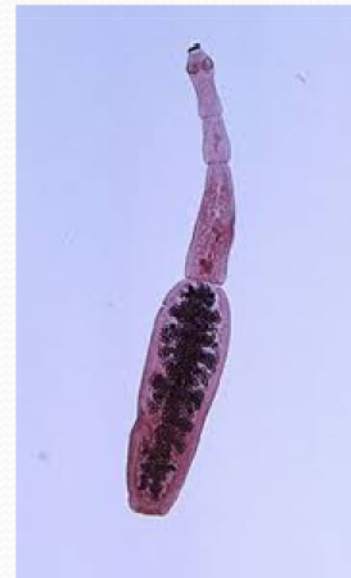- فحص 2650 رأس غنم و 900 رأس ماعز ذبحت في المسلخ بحماه بهدف تحري إصابتها بالكيسات المائية (التي تهمنا):
- نسبة الإصابة بالغنم 10% و الماعز 22%

- إصابة غنم رعوي 32% حظائر 1%
- = ماعز رعوي 25% حظائر 8%

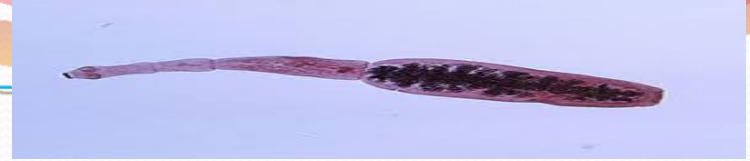
- = غنم أقل من سنة 7% أكبر من سنة 30%
- = ماعز = = 20% = = = 30%

Complications of the Pulmonary Hydatid Cysts Disease

- *Small intact cyst is generally asymptomatic .*
- *The symptoms appear :*
 - *Large cyst*
 - *Development of complications.*



Complications of the Pulmonary Hydatid Cysts Disease

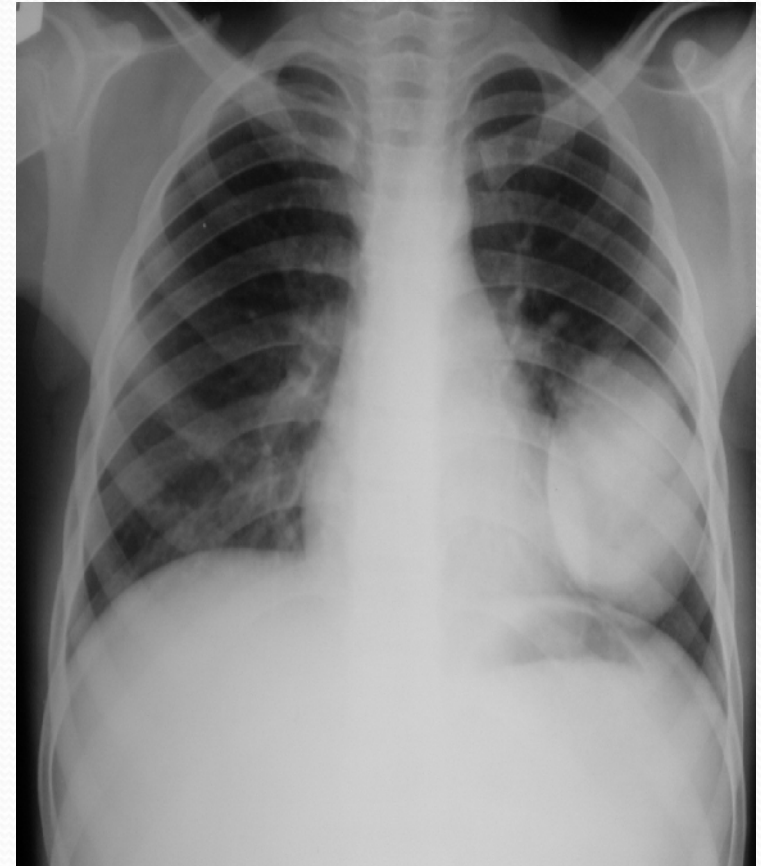


- ***1- Complications of intact cysts***
- ***2- Complications related to hydatid cyst rupture specially into the bronchial tree.***
- ***3- Pleural complications***
- ***4- Thorax wall complications***
- ***5- Respiratory system complications from the hydatid cysts in the liver***
- ***6- Systemic complications***

Complications of Pulmonary Hydatid Cysts Disease

Intact Hydatid Cyst

- ***Homogenous, well defined, round or oval shadow***
- ***Intact Cysts is Usually asymptomatic***



Complications of Pulmonary Hydatid Cysts Disease

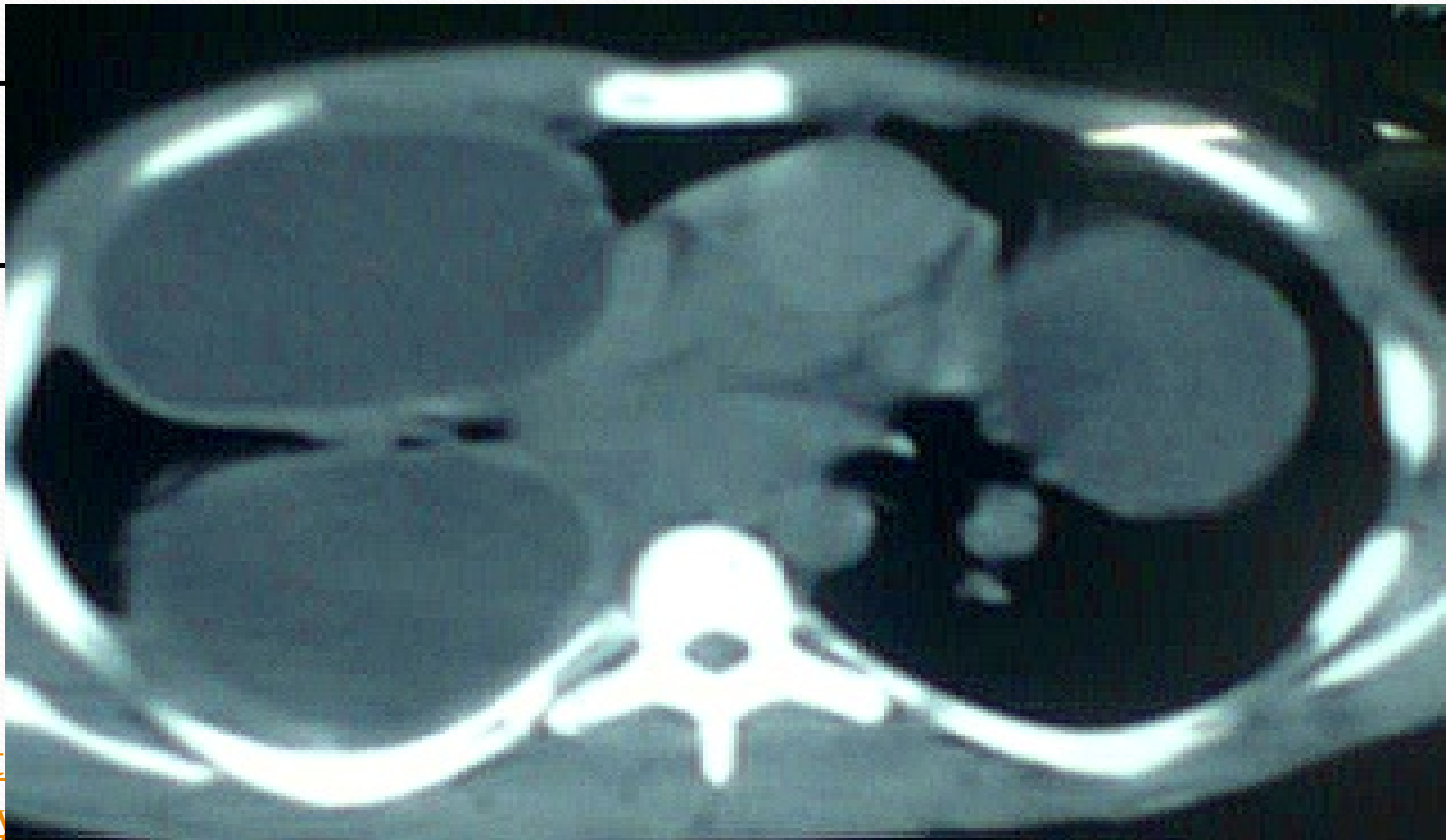1- Compression on the adjacent organs

● A-

●

● B-

●



*Ufuk
, Peert

e Lung

**7. Say

al

experience in patients with pulmonary cyst hydatid. Int J Clin Exp Med 5: 64-71.]

***9. Çobanoğlu U, Sayır F, Mergan D (2011) Diagnostic Dilemma: Analysis of 11 Cases of Hydatid Disease. Türkiye Parazitol Derg 35: 164-168.



Complications of Pulmonary Hydatid Cysts Disease

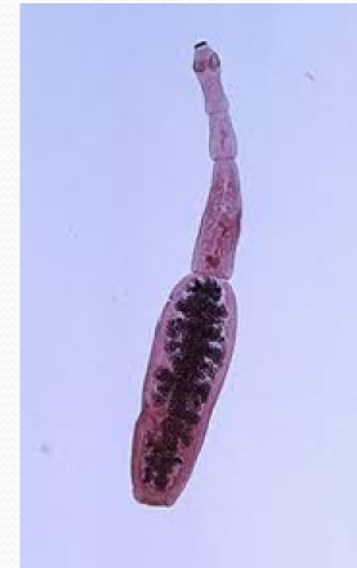1- Compression on the adjacent organs

- ***B- Large cysts may lead to pressure (10% of the large cyst):***
 - *Mediastinum.....Mediastinal shift*
 - *The esophagusDysphagia*
 - *heart..... Cardiac malposition and arrhythmia*
 - *tracheaDyspnea and stridor,*
 - *veinsVena Cava Superior Syndrome*
 - ***Rarely : Atelectasis , pneumonia, destruction***


Complications of Pulmonary Hydatid Cysts Disease

2- Complications Related to Hydatid Cyst Rupture to the bronchial system

- 25-50%



*Yekeler E, Karaoğlanoğlu N (2012) Akciğerin Parasitic Diseases of the Lung: Hydatid Cyst Complications. Türkiye Klinikleri J Thor Surg Special Topics 5: 157-164



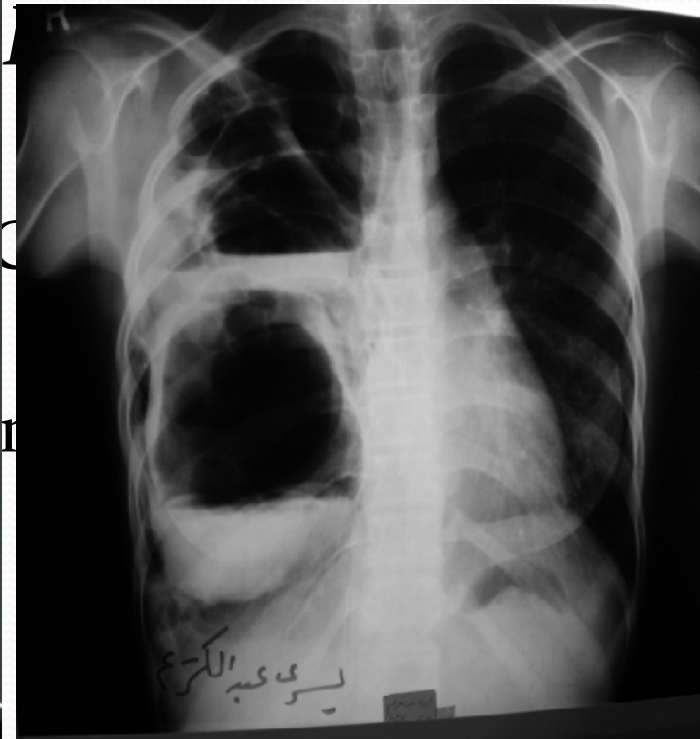
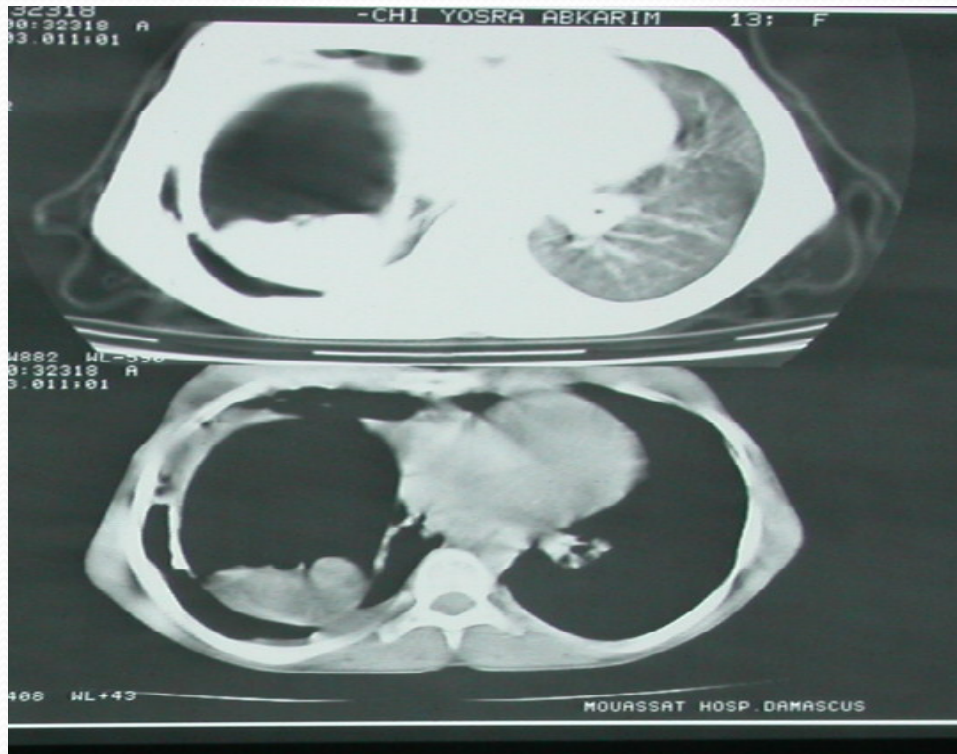
Complications of Pulmonary Hydatid Cysts Disease

2- Complications Related to Hydatid Cyst Rupture to the bronchial system

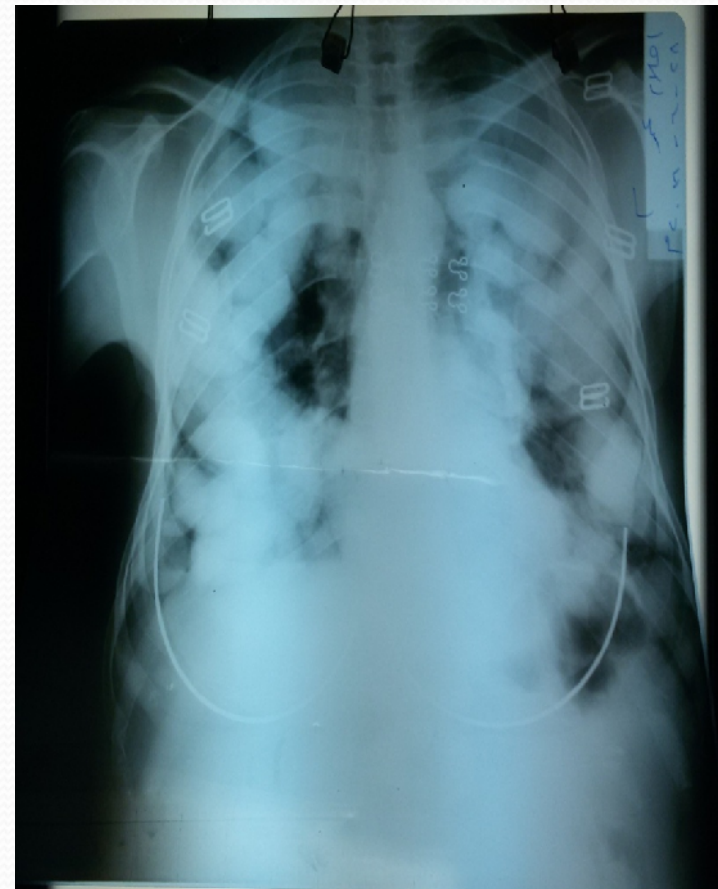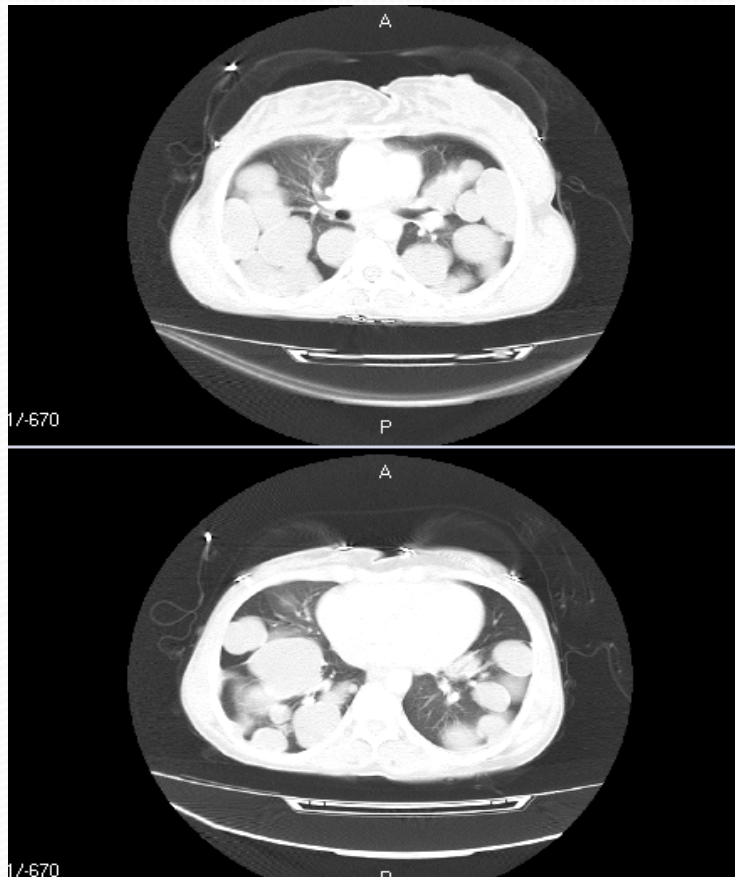
- *Asphyxia*
- *Hemoptysis,*
- *Pneumonia (reaction and infected pneumonia), pulmonary abscess*
- *Anaphylactic shock*

- *Aspergilloma in the cyst cavity*
- *Disseminated pulmonary hydatidosis*

Complications Related to Hydatid Cyst Rupture to the bronchial system



Disseminated pulmonary hydatidosis

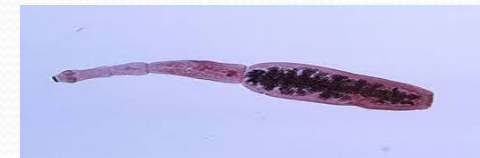

Complications of Pulmonary Hydatid Cysts Disease

3- Pleural complications (5-13%)

- *Rupture of the lung cyst into the pleural cavity**
 - *Pneumothorax, hydropneumothorax, tension pneumothorax,*
 - *Empyema, bronchopleural fistula,*
 - *Pleuritis and pleural thickening, trapped lung,*
 - *Secondary disseminated pleural hydatid disease*

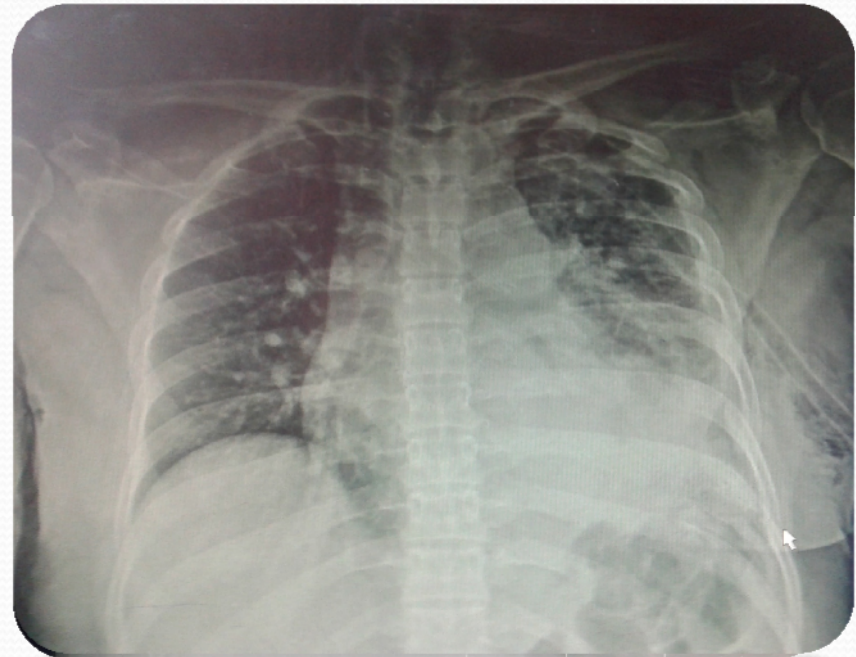,88. Kılıç D, Fındıkcıoğlu A, Bilen A, Koç Z, Hatipoğlu A (2007)
Management of complicated hydatid cyst of the thorax. ANZ J Surg 77: 752-757.
,1515. Aribas OK, Kanat F, Görmüş N, Türk E (2002)
Pleural complications of hydatid disease.
J Thorac Cardiovasc Surg 123: 492-497.



Complications of Pulmonary Hydatid Cysts Disease

3- Pleural complications

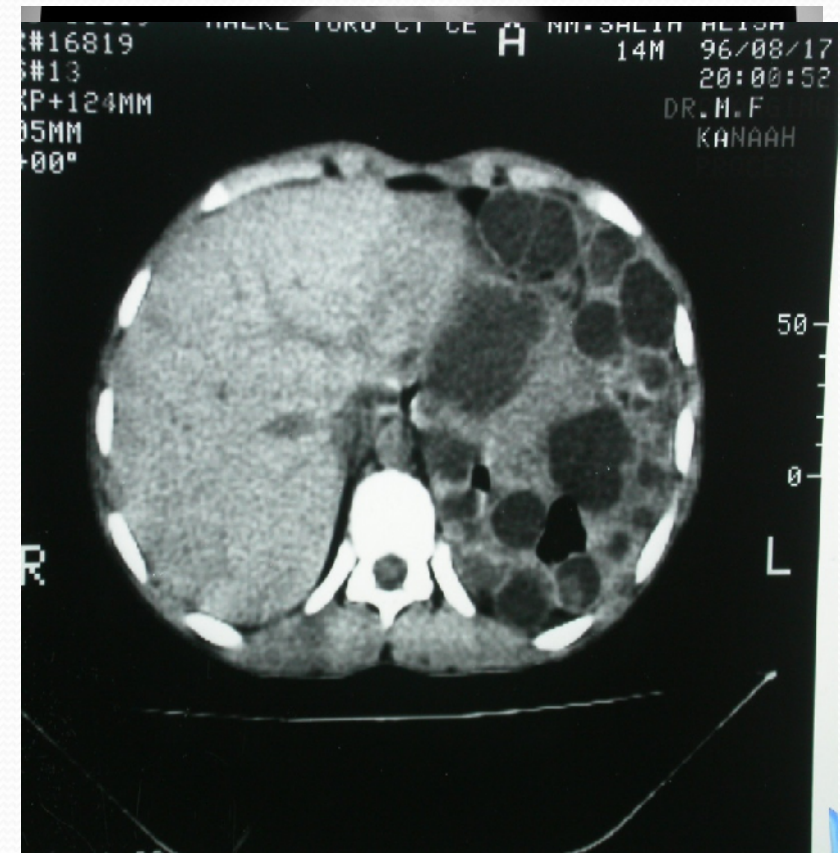- *Hyrdopneumothorax
Refractory to chest
drainage.
Need early surgical
treatment*



Complications of Pulmonary Hydatid Cysts Disease

3- ***Pleural complications***

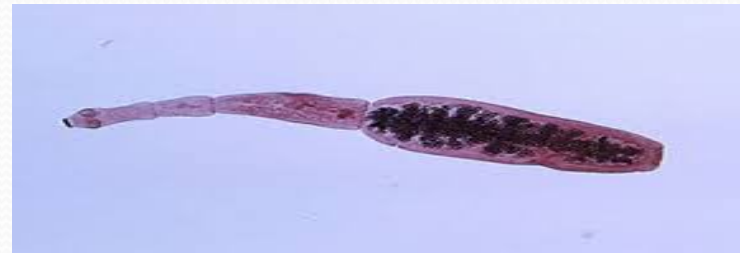- 9 y-old boy
- 4 years ago, Chest drainage
- Now white hemithorax
- Disseminated pleural hydatidosis



Complications of Pulmonary Hydatid Cysts Disease

4-Thorax wall complications(1-2%)

- *Bone destruction .
Radiologically imitate tumors .*
- *Vertebral destruction and severe neurologic disease .*

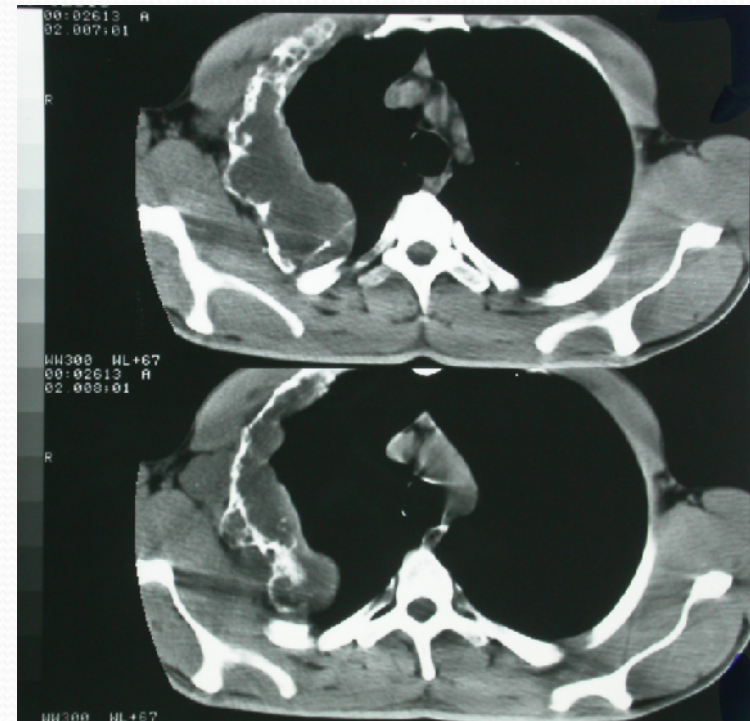
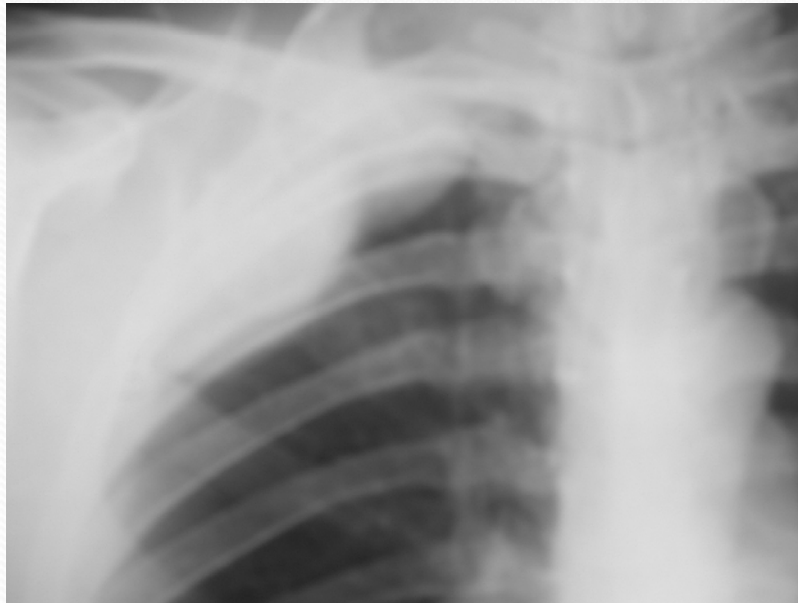

Complications of Pulmonary Hydatid Cysts Disease

4-Thorax wall complications(1-2%)

Thorax Wall Hydatid Cysts

- Costal Hydatid Cysts

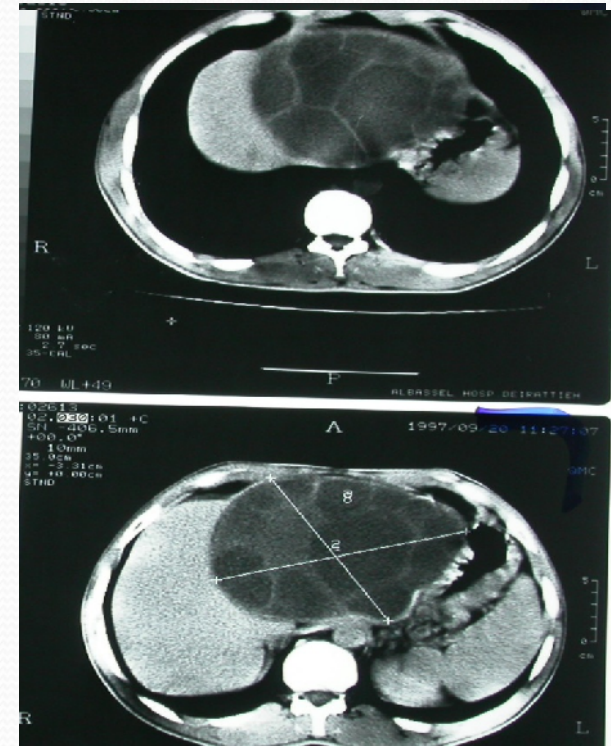
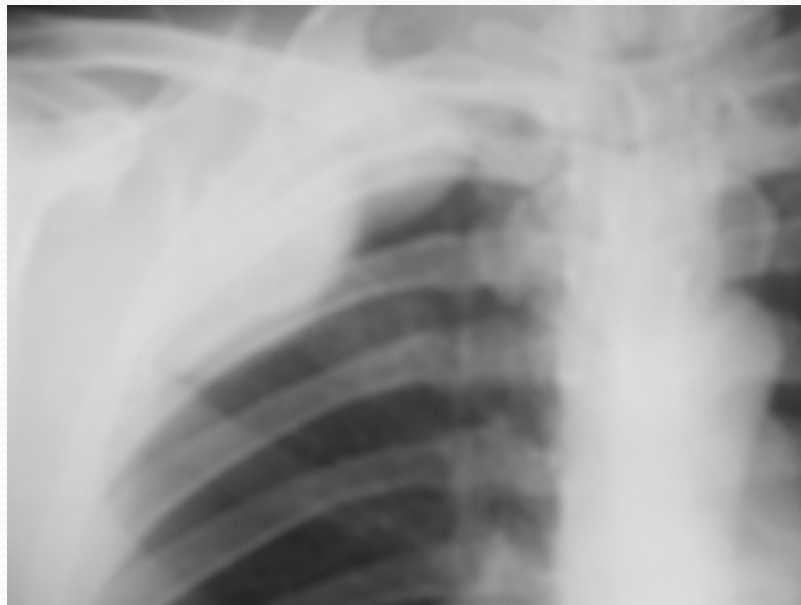

4-Thorax wall complications(1-2%)

4-Thorax wall complications(1-2%)

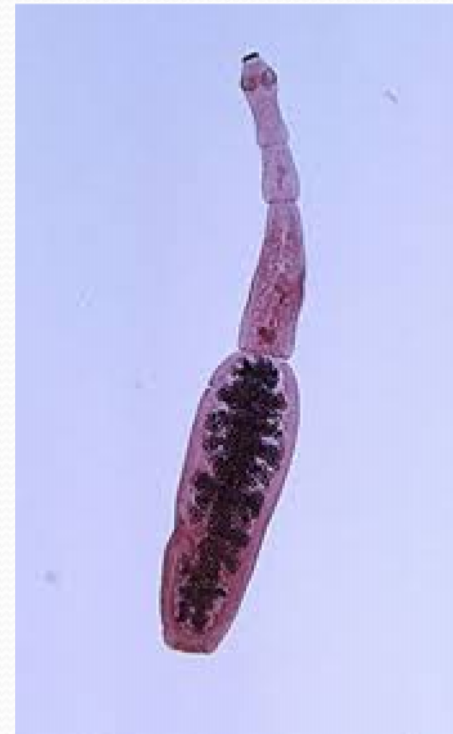*Hydatid cysts destroyed the rib
With large Hepatic Cyst*

With large Hepatic Cyst



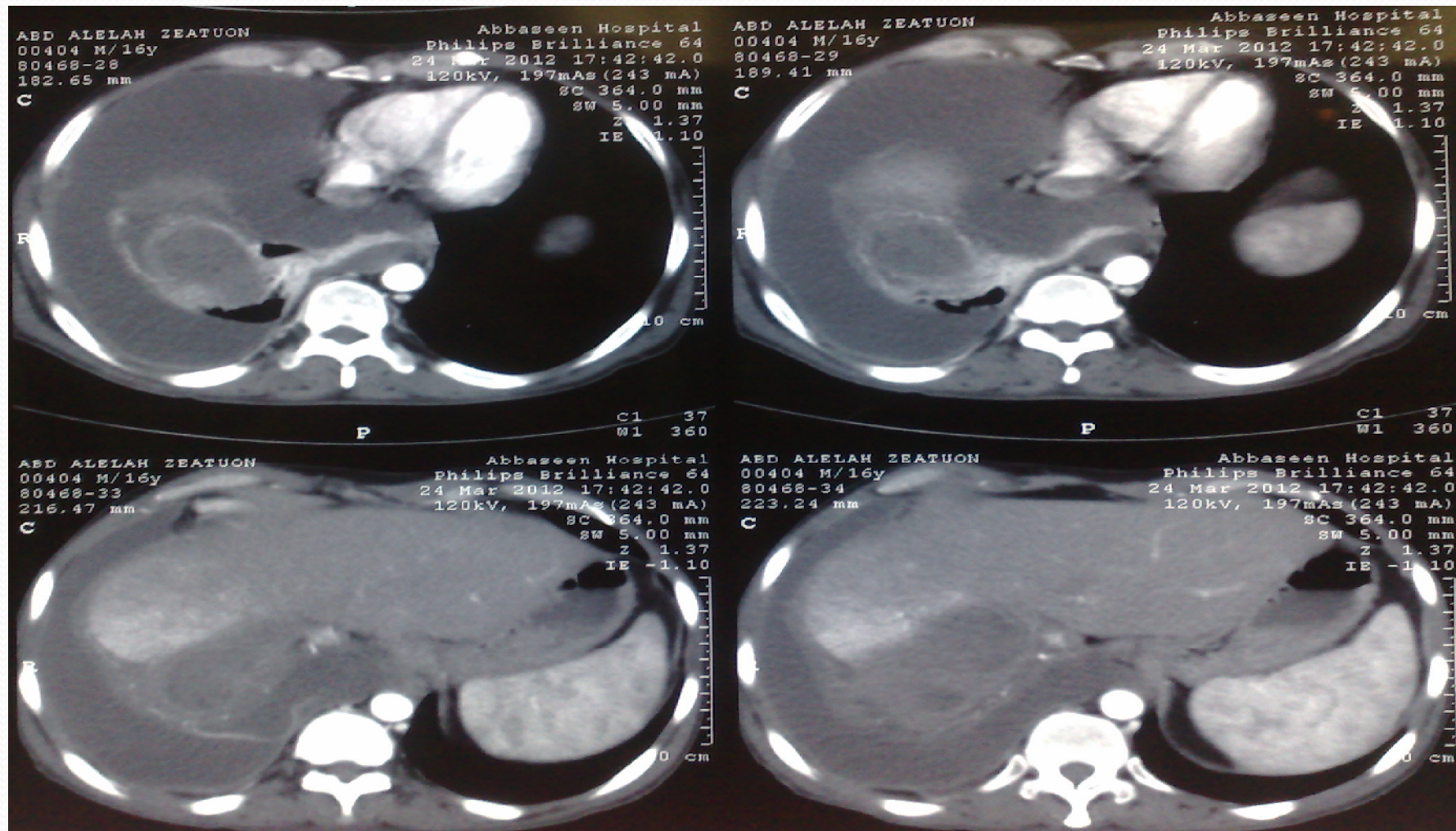
Complications of Pulmonary Hydatid Cysts Disease
**5- Respiratory system complications of the
hydatid cysts in the liver (rate of 0.6-16%)**

- *Perforation to thorax:*
 - *Pleural effusion,*
 - *Empyema,*
 - *Parenchymal destruction*
 - *Billobronchial fistula.*
- *High mortality (9-43%)*



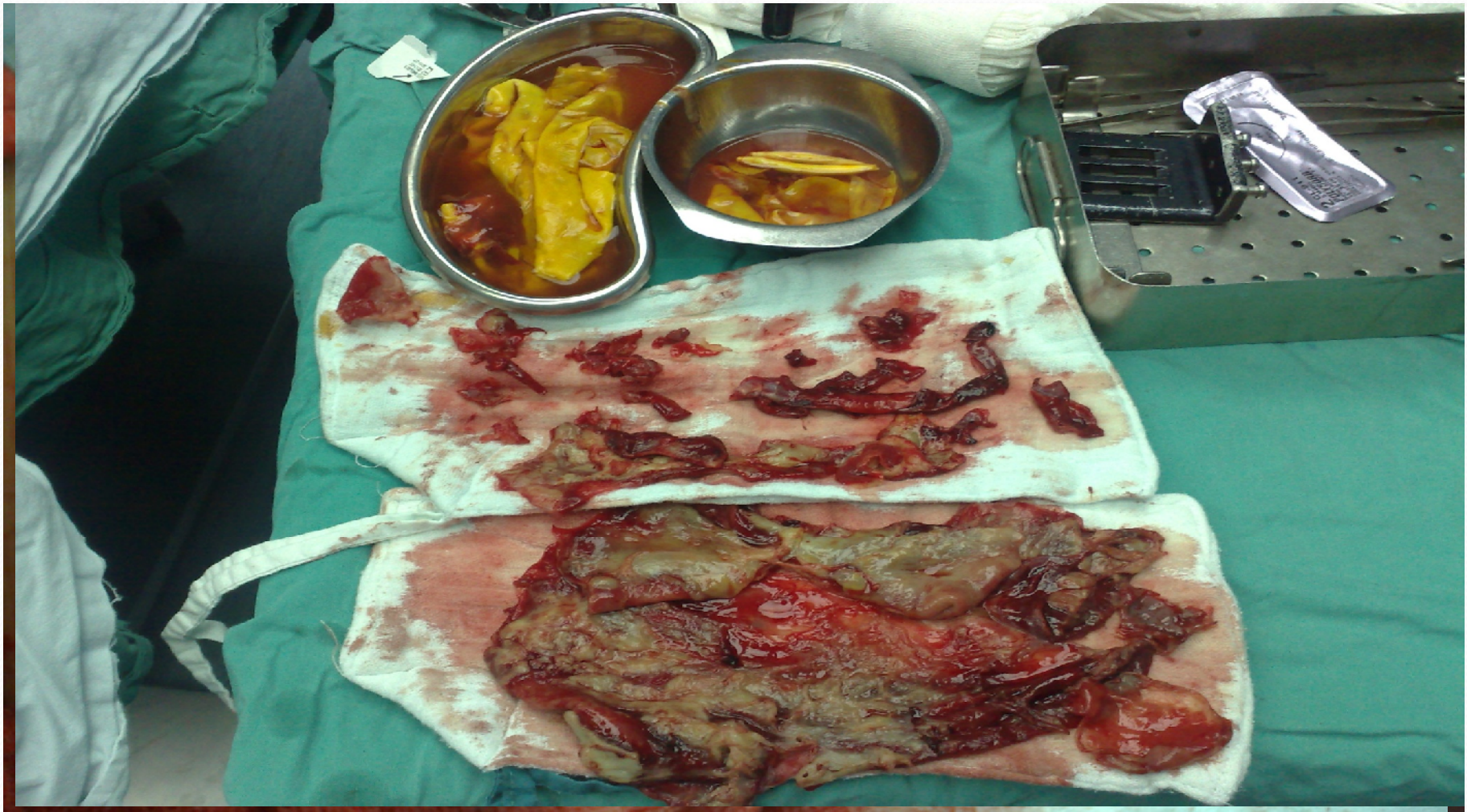Complications of Pulmonary Hydatid Cysts Disease

5- Respiratory system complications of the hydatid cysts in the liver (rate of 0.6-16%)



Complications of Pulmonary Hydatid Cysts Disease

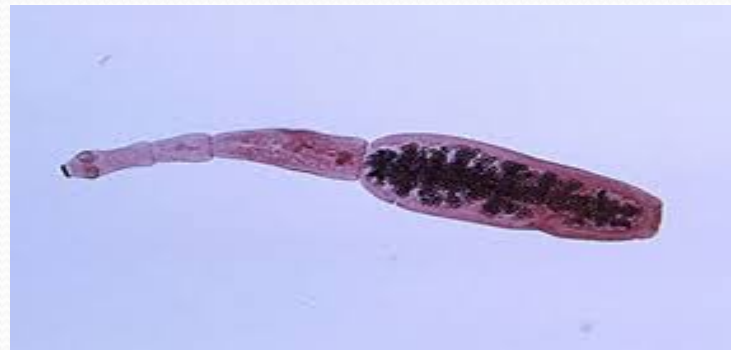5- Respiratory system complications of the hydatid cysts in the liver (rate of 0.6-16%)



Complications of Pulmonary Hydatid Cysts Disease

6- Systemic complications (8%)

- ***Simple allergic reaction : chest pain, itching, urticarial , flushing , bronchospasm***
- ***Anaphylaxis and shock and very rarely death.***



Clinical and Radiological Manifestations of 206 Patients with Pulmonary Hydatidosis over 10 year Period



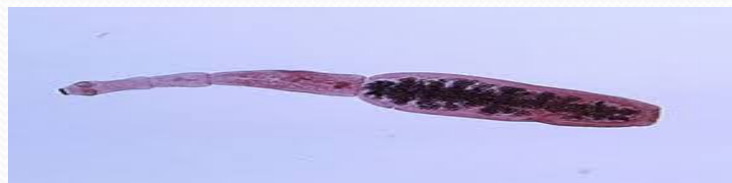- ***Darwish, B., Clinical and Radiological Manifestations of 206 Patients with Pulmonary Hydatidosis over 10 year Period, Primary Care Respiratory Journal (2006) 15,246-251.***

Clinical presentations of pulmonary hydatidosis in our 206 Patients

Symptoms	Our study in Syria
Asymptomt.	18%
Cough	54%
Chest pain	36%
Dyspnea	25%
Hemoptysis	19%
Hydroemesis	10%
Infection	10%
Pleuritis	5%
Pneumothorax	3%
Total pts.	206


Conclusion of Complications of Pulmonary Hydatid Cysts Disease

- *The symptoms of the pulmonary hydatid cyst appear with pressure on the adjacent organs **by large cyst and during the development of complications.***
- *Complicated Pulmonary Hydatid cysts present with **many different clinical and radiological findings.***
- *But most cases diagnosed **radiologically.***
- *Some cases develop **difficult medical condition.***





Thank you for your attention



Almouassat University *Hospital*, Damascus

